River Publishers

Image Registration and Image Segmentation for Image- Guided Radiotherapy of Prostate Cancer

Author: Anne Sofie Korsager, Department of Health Science and Technology, Aalborg University, Denmark

Medical imaging plays a key role in treatment of various cancer types and in particular in image-guided radiotherapy (IGRT) and can be used in all stages of the radiotherapy treatment including accurate target delineation and radiation dose calculations in the planning of IGRT. Magnetic resonance (MR) imaging is often used for accurate soft-tissue delineation and computed tomography (CT) images are used for radiation dose calculations. The accurate target delineation together with multimodal imaging may enable a smaller radiation field. This is important in IGRT as it enables a high radiation dose to the target and minimizes the radiation dose to the surrounding healthy tissue, which results in an improved treatment outcome with lower toxicity and reduced side-effects.

The use of multimodal imaging requires alignment of MR and CT in order to map the target delineation in MR to CT for dose calculations. The target delineation and the image alignment are today widely performed manually and are therefore time-consuming, labor-intensive, and prone to observer variations. The target for radiation is extended to include healthy tissue to ensure that the tumor is always radiated during treatment as a consequence of the observer variation together with other uncertainties.

. The thesis seeks to address these challenges in the planning of radiotherapy of prostate cancer. Prostate cancer is a cancer type where the treatment highly benefits from the use of IGRT and multimodal imaging. The prostate is delineated as the target in MR because of the good soft-tissue visualization in MR and a following image alignment enables dose calculations based on CT. At Aalborg University Hospital a newly developed removable Ni-Ti prostate stent is implanted into the prostate gland and is used as a fiducial marker to achieve an accurate alignment of the prostate in MR and CT. The first part of the thesis focuses on automatic image alignment using voxel similarity and on a comparison of the automatic approach with the current clinical approach. The second part focuses on automatic target delineation. Two automatic approaches for target delineation in MR using both voxel intensities and knowledge about the shape are developed and validated.

The approaches presented are expected be adaptable to target delineation and image alignment of other soft-tissue organs.

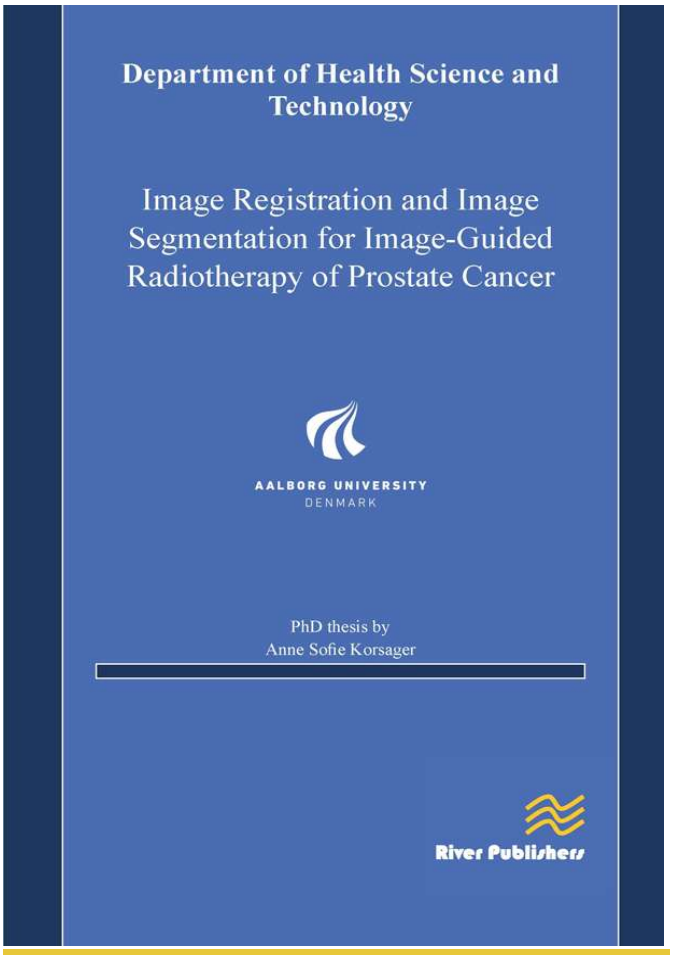

River Publishers Series in open

e-ISBN: 9788793237292
Available From: December 2014
Price:

KEYWORDS:
Image Registration and Image Segmentation for Image- Guided Radiotherapy of Prostate Cancer

www.riverpublishers.com
marketing@riverpublishers.com